Cortical gray matter-white junction pattern of retention of the tauopathy ligand ^{18}F-T807 (Avid-1451) in clinically probable CTE

Dara L. Dickstein PhD

Icahn School of Medicine at Mount Sinai

Departments of Neuroscience, Geriatrics & Palliative Medicine

Icahn School of Medicine at Mount Sinai

“Early Days” Exploration of Molecular Imaging in TBI and CTE: Many Unsettled “Moving Parts”

- Well-defined conditions (e.g., AD, FTD) vs relatively recently identified conditions (e.g., CTE, PART)
- Multiple structural pathologies (amyloidosis, tauopathy)
- Well-characterized ligands (e.g., florbetapir) as well as new ligands (e.g., T807/AV1451)
- Range of time courses (e.g., acute, chronic) and severities (e.g., mild repetitive, moderate-severe)
- Clinicoradiological and clinicopathological correlation by disease entity and eventually by patient (i.e., autopsy, available in AD, not yet available in other tauopathies)

Amyloid PET ligands*

Pittsburgh Compound B

Florbetapir (AV-45)

Florbetaben

Flutemetamol

*All FDA approved
Reimbursed only in clinical trials

Tauopathy PET ligands

T807/AV1451

PBB3

Tohoku (THK) series

Amyloid imaging in acute TBI

- Despite pathology reports that most acute amyloid deposition is diffuse amyloid that would be predicted to binds PiB only weakly, acute TBI imaging has revealed PiB retention

- Verified in tissue slices by Menon

- PiB retention likely in moderate to severe TBI with visible contusions on MRI

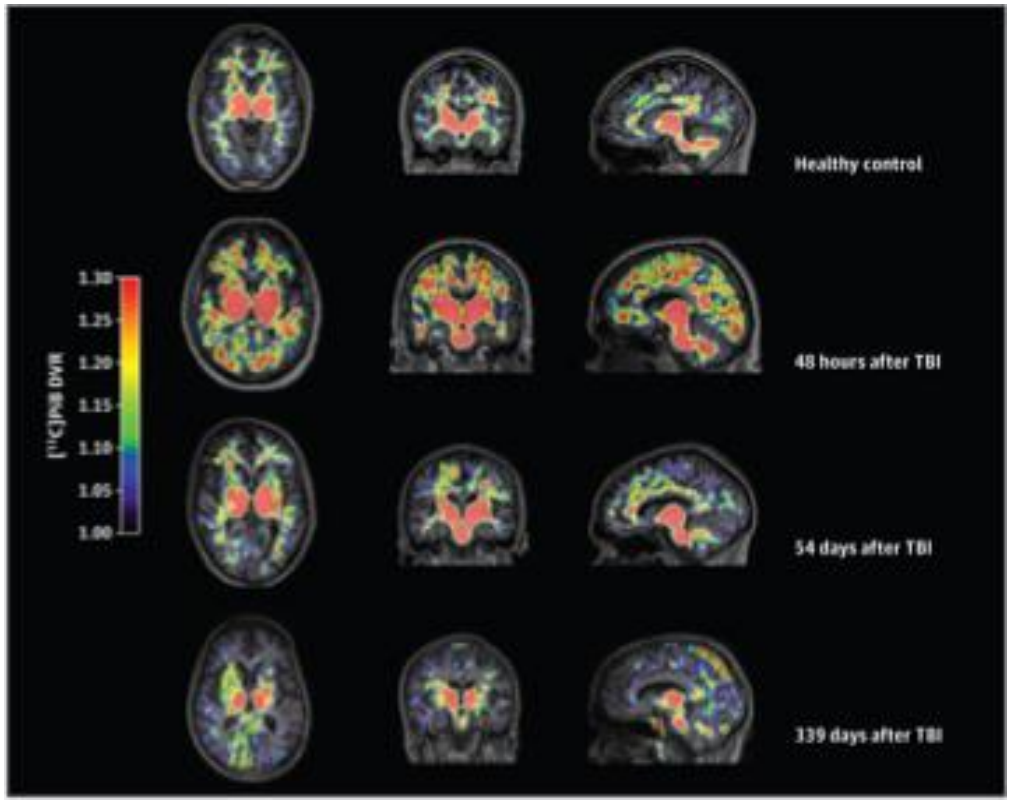

- **Boxer Post KO Amyloid Imaging Project -** Amyloid imaging within 1 month of most recent LOC/KO - Amyloid im aging within 1 month of most recent LOC/KO

(Jordan, Kostakoglu, Stone, Dickstein, Gandy, unpublished observations)

Amyloid imaging in chronic TBI

- Definitely associated with severe TBI and poor outcome

- DP studies by Jordan *et al JAMA* 1997 suggests *APOE* genotype modulates cognitive outcome; role here currently unknown (Role of *APOE* genotype unknown (predict E4 more amyloidogenic than E3 or E2)

- Kawai *et al Brain Injury* 2013 – PiB retention in 3 out of 12 cases. These 3 cases were most severely impaired

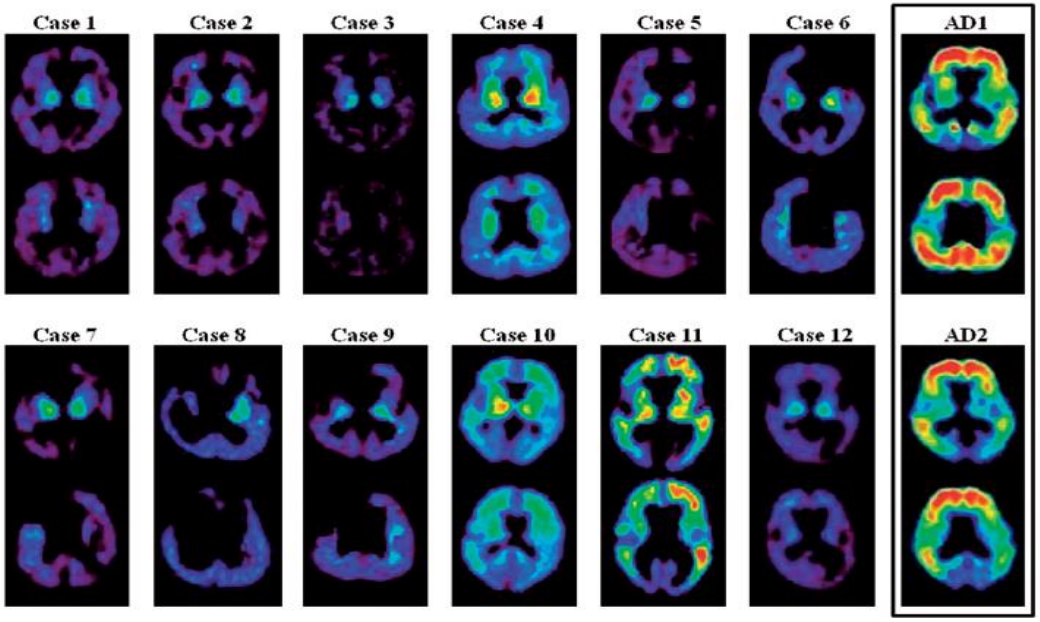

- Positive amyloid imaging may represent evolution to AD, though 50% of CTE cases have amyloid deposits

Newly recognized tauopathy: Primary aging-related tauopathy (PART)

CONSENSUS PAPER

Primary age-related tauopathy (PART): a common pathology associated with human aging

John F. Crary · John Q. Trojanowski · Julie A. Schneider · Jose F. Abisambra · Erin L. Abner · Irina Alafuzoff · Steven E. Arnold · Johannes Attems · Thomas G. Beach · Eileen H. Bigio · Nigel J. Cairns · Dennis W. Dickson · Marla Gearing · Lea T. Grinberg · Patrick R. Hof · Bradley T. Hyman · Kurt Jellinger · Gregory A. Jicha · Gabor G. Kovacs · David S. Knopman · Julia Kofler · Walter A. Kukull · Ian R. Mackenzie · Eliezer Masliah · Ann McKee · Thomas J. Montine · Melissa E. Murray · Janna H. Neltner · Ismael Santa-Maria · William W. Seeley · Alberto Serrano-Pozo · Michael L. Shelanski · Thor Stein · Masaki Takao · Dietmar R. Thal · Jonathan B. Toledo · Juan C. Troncoso · Jean Paul Vonsattel · Charles L. White 3rd · Thomas Wisniewski · Randall L. Woltjer · Masahito Yamada · Peter T. Nelson

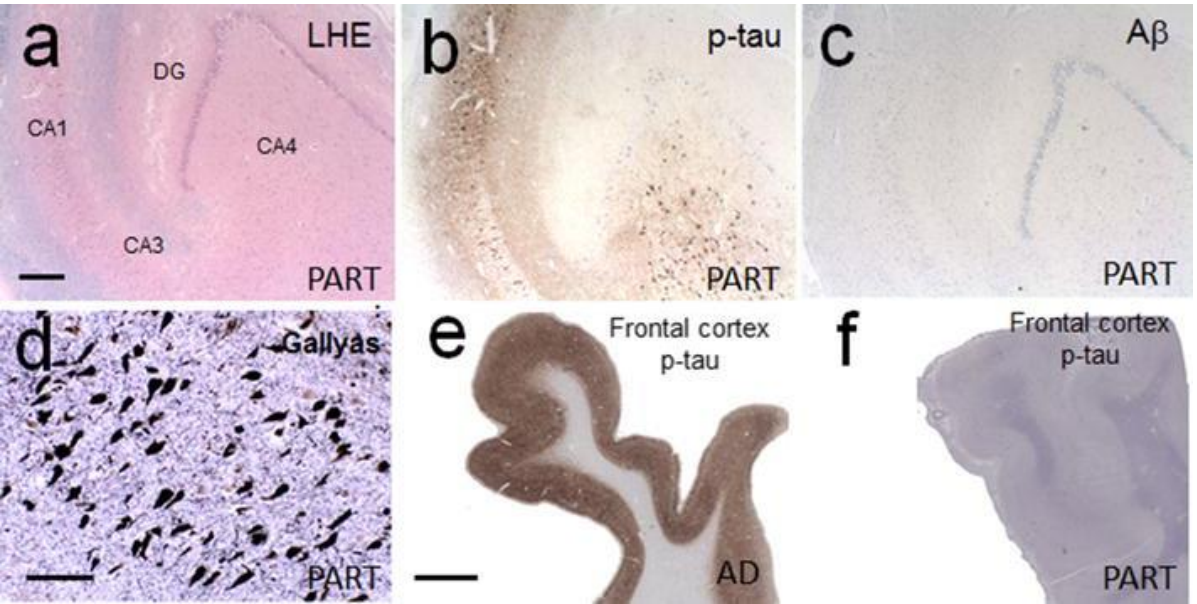

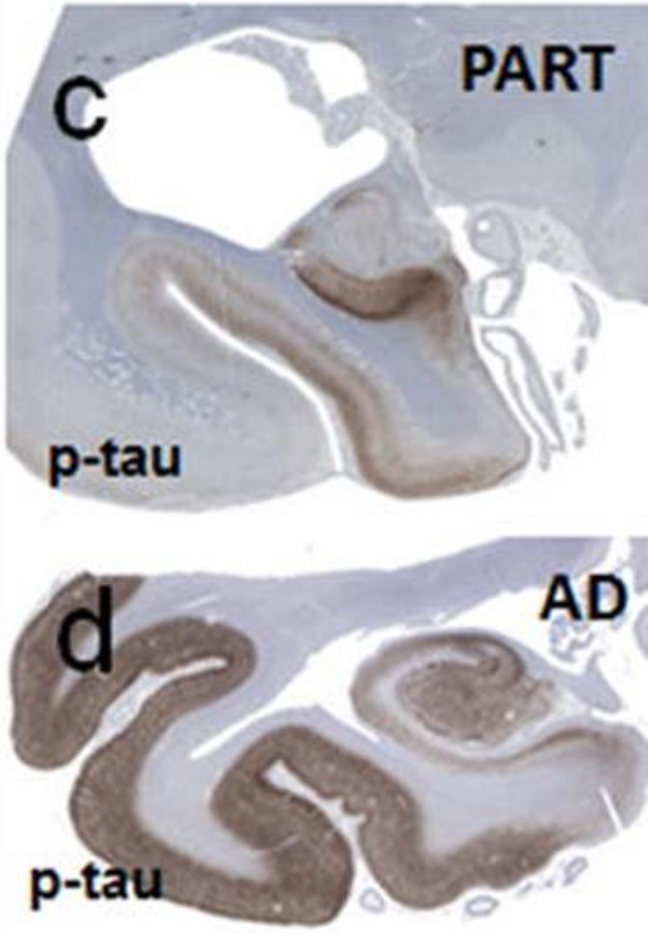

OPEN

Citation: Transl Psychiatry (2014) 4, e441; doi:10.1038/tp.2014.91
© 2014 Macmillan Publishers Limited All rights reserved 2158-3188/14
www.nature.com/tp

CASE REPORT

Tauopathy PET and amyloid PET in the diagnosis of chronic traumatic encephalopathies: studies of a retired NFL player and of a man with FTD and a severe head injury

EM Mitsis[1,2,3,*], S Riggio[1,3,4,5], L Kostakoglu[6], DL Dickstein[2,7], J Machac[6], B Delman[8], M Goldstein[4], D Jennings[9], E D'Antonio[10], J Martin[1], TP Naidich[8], A Aloysi[1], C Fernandez[1,2,3], J Seibyl[9], ST DeKosky[11], GA Elder[1,3,4], K Marek[9], W Gordon[3,10], PR Hof[2,7], M Sano[1,2,3] and S Gandy[1,2,3,4,5]

Journal of Alzheimer's Disease 34 (2013) 457–468
DOI 10.3233/JAD-122059
IOS Press

Early Clinical PET Imaging Results with the Novel PHF-Tau Radioligand [F-18]-T807

David T. Chien[a], Shadfar Bahri[b], A. Katrin Szardenings[a], Joseph C. Walsh[a], Fanrong Mu[a], Min-Ying Su[b], William R. Shankle[c], Arkadij Elizarov[a] and Hartmuth C. Kolb[a,*]
[a]*Siemens Molecular Imaging, Inc., Culver City, CA, USA*
[b]*Tu and Yuen Center for Functional Onco-Imaging, Department of Radiological Sciences, University of California Irvine, CA, USA*
[c]*Shankle Clinic Memory and Cognitive Disorders Program, Hoag Neurosciences Institute, Newport Beach, CA,*

Tau PET with [18f]AV1451 in Non-Alzheimer's Disease Neurodegenerative Syndromes

Abstract ID: 5289

View Session Detail to Add to Schedule

Author block: Gil D Rabinovici, MD[1,2,3]; Daniel Schonhaut, BA[1,2]; Suzanne Baker, PhD[1]; Andreas Lazaris, BS[2]; Rik Ossenkoppele, PhD[2,4]; Sam Lockhart, PhD[5]; Michael Schöll, PhD[1]; Henry Schwimmer, BA[1]; Jacob W Vogel, BA[6]; Nagehan Ayakta, BS[2]; Howard Rosen, MD[2]; Bruce L Miller, MD[2]; James P. O'Neil, PhD[3]; Adam L Boxer, MD, PhD[2] and William J Jagust, MD[1,2,3], (1)University of California Berkeley, Berkeley, CA, USA, (2)University of California San Francisco, San Francisco, CA, USA, (3)Lawrence Berkeley National Laboratory, Berkeley, CA, USA, (4)VU University Amsterdam, Amsterdam, Netherlands, (5)UC Berkeley, Berekeley, CA, USA, (6)UC Berkeley, Berkeley, CA, USA

In vivo characterization of chronic traumatic encephalopathy using [F-18]FDDNP PET brain imaging

Jorge R. Barrio[a,1], Gary W. Small[b], Koon-Pong Wong[a], Sung-Cheng Huang[a], Jie Liu (刘捷)[a], David A. Merrill[b], Christopher C. Giza[c], Robert P. Fitzsimmons[d], Bennet Omalu[e], Julian Bailes[f], and Vladimir Kepe[a,1]

In vivo characterization of chronic traumatic encephalopathy using [F-18]FDDNP PET brain imaging

Jorge R. Barrio[a,1], Gary W. Small[b], Koon-Pong Wong[a], Sung-Cheng Huang[a], Jie Liu (刘捷)[a], David A. Merrill[b], Christopher C. Giza[c], Robert P. Fitzsimmons[d], Bennet Omalu[e], Julian Bailes[f], and Vladimir Kepe[a,1]

II. Amygdala and Dorsal Midbrain: core regions in [F-18]FDDNP PET

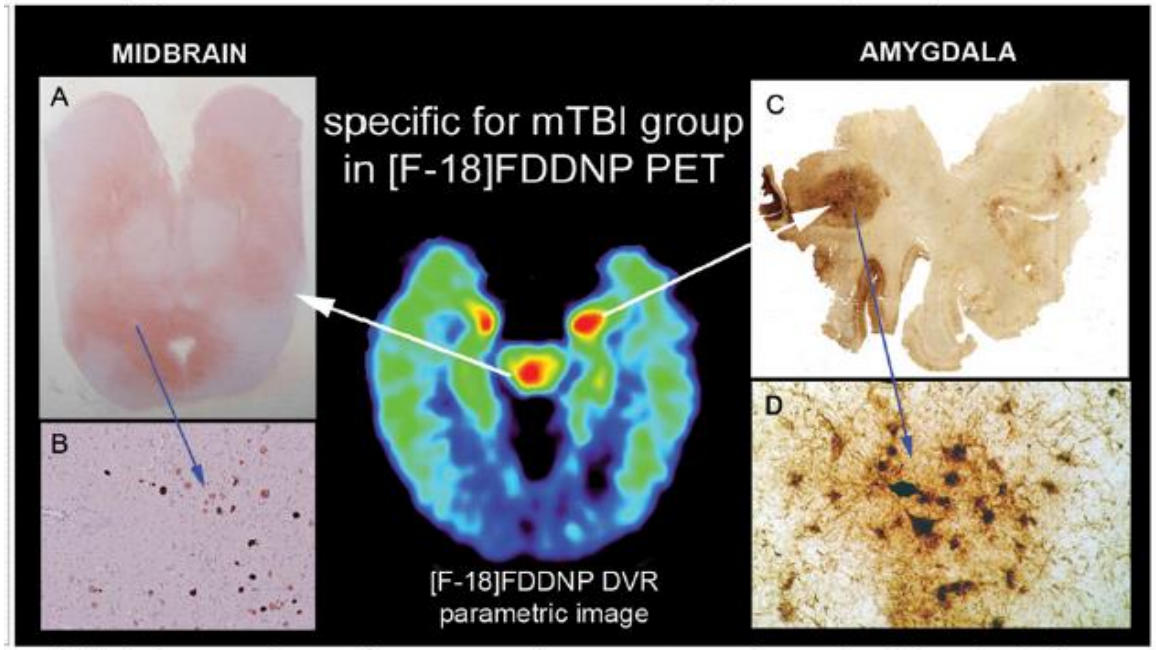

- Clinicoradiological correlation between FDDNP signal and tauopathy.
- Mesial temporal FDDNP c/w typical CTE but brainstem only positive in very severe CTE.

Is brainstem FDDNP authentic tauopathy?

Tau PET with [18f]AV1451 in Non-Alzheimer's Disease Neurodegenerative Syndromes

Abstract ID: 5289

View Session Detail to Add to Schedule

Author block: Gil D Rabinovici, MD[1,2,3]; Daniel Schonhaut, BA[1,2]; Suzanne Baker, PhD[1]; Andreas Lazaris, BS[2]; Rik Ossenkoppele, PhD[2,4]; Sam Lockhart, PhD[5]; Michael Schöll, PhD[1]; Henry Schwimmer, BA[1]; Jacob W Vogel, BA[6]; Nagehan Ayakta, BS[2]; Howard Rosen, MD[2]; Bruce L Miller, MD[2]; James P. O'Neil, PhD[3]; Adam L Boxer, MD, PhD[2] and William J Jagust, MD[1,2,3], (1)University of California Berkeley, Berkeley, CA, USA, (2)University of California San Francisco, San Francisco, CA, USA, (3)Lawrence Berkeley National Laboratory, Berkeley, CA, USA, (4)VU University Amsterdam, Amsterdam, Netherlands, (5)UC Berkeley, Berekeley, CA, USA, (6)UC Berkeley, Berkeley, CA, USA

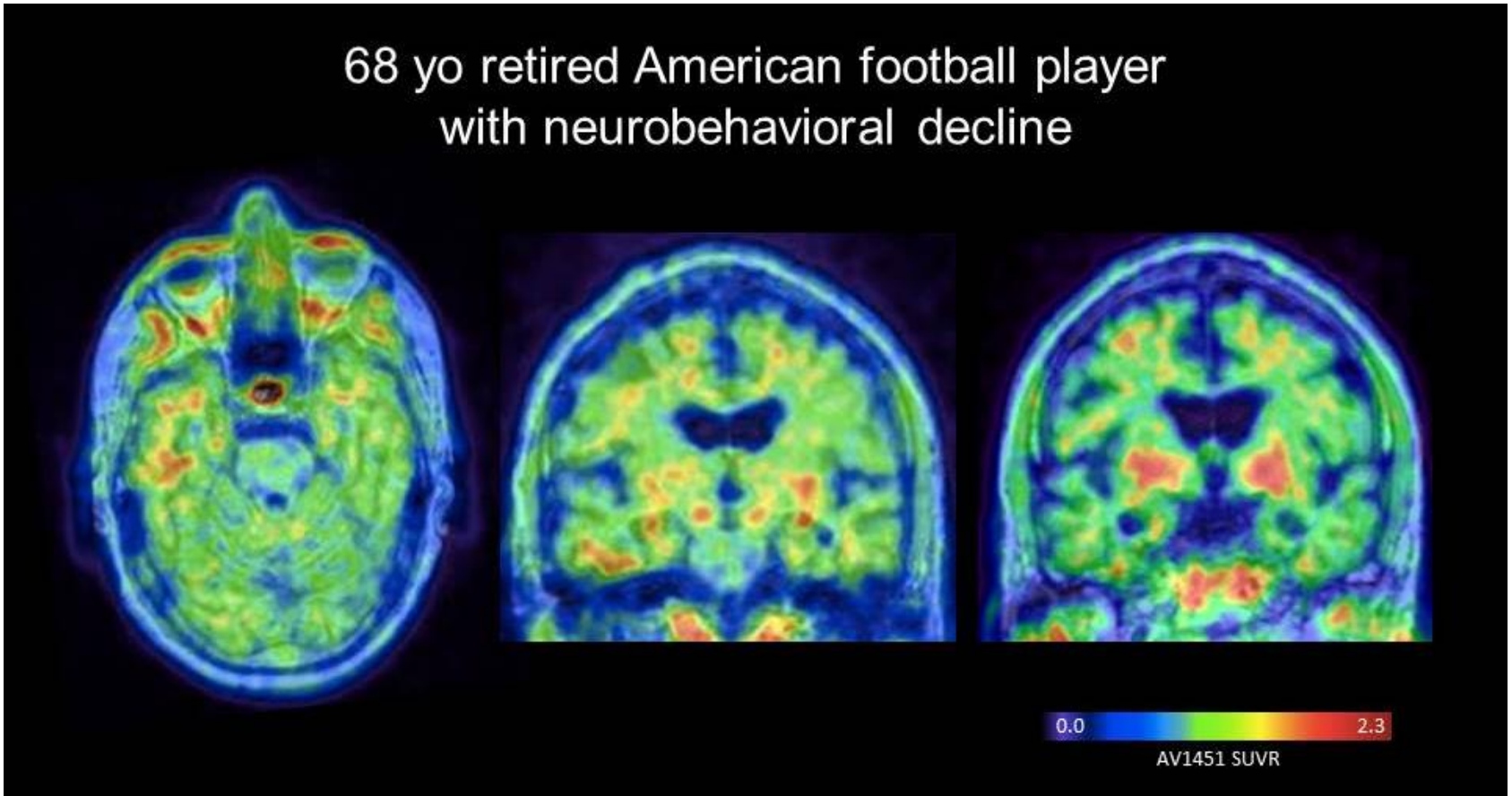

CASE REPORT

Tauopathy PET and amyloid PET in the diagnosis of chronic traumatic encephalopathies: studies of a retired NFL player and of a man with FTD and a severe head injury

EM Mitsis[1,2,3,*], S Riggio[1,3,4,5], L Kostakoglu[6], DL Dickstein[2,7], J Machac[6], B Delman[8], M Goldstein[4], D Jennings[9], E D'Antonio[10], J Martin[1], TP Naidich[8], A Aloysi[1], C Fernandez[1,2,3], J Seibyl[9], ST DeKosky[11], GA Elder[1,3,4], K Marek[9], W Gordon[5,10], PR Hof[2,7], M Sano[1,2,3] and S Gandy[1,2,3,4,5]

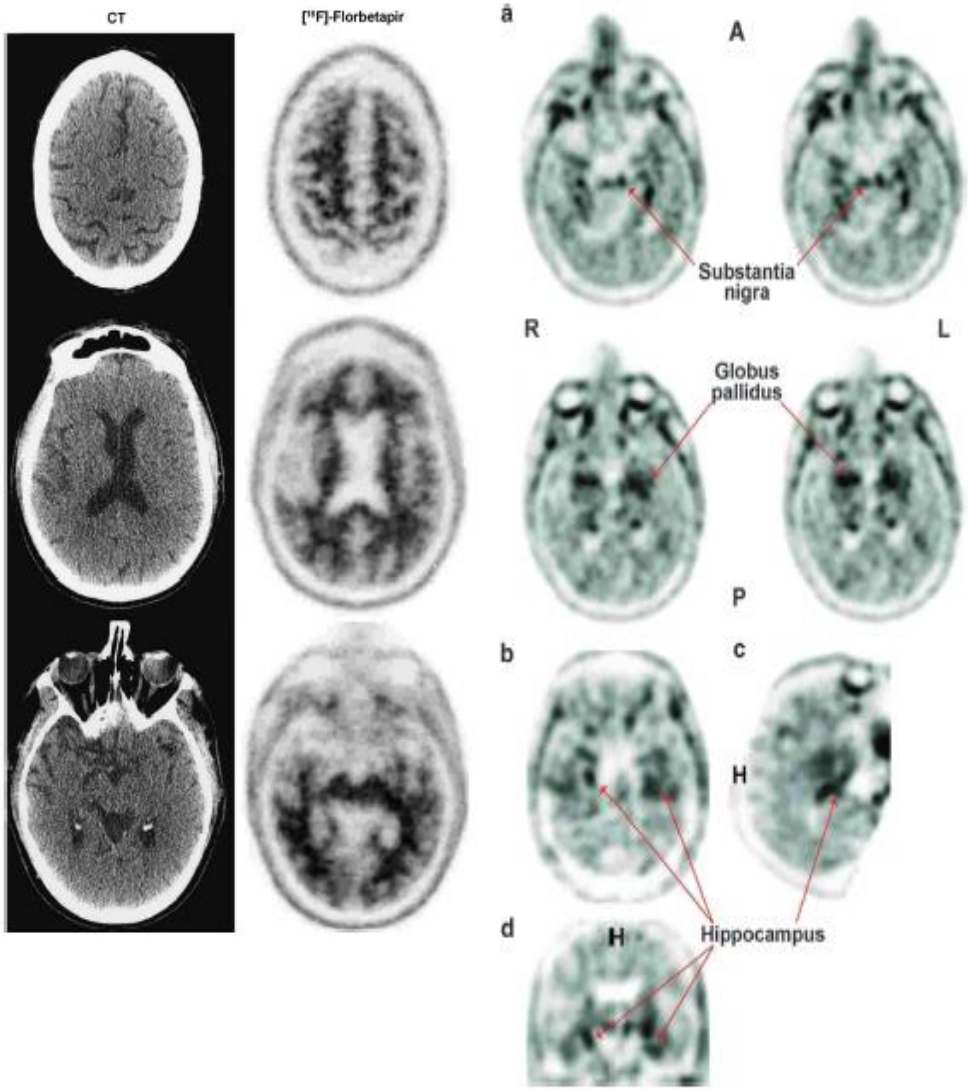

- Retired 70 yr old former NFL player with hundreds of concussions.
- Memory disorder, PSP-like exam.
- Mesial temporal T807 signal appears authentic.
- Not clear clinical severity sufficient for midbrain path.
- Striatum may be artifact or may relate to CTE/PSP

Research Question:

Can we identify CTE and distinguish it from AD using imaging and cognitive assessment?

- Utilize both [^{18}F]-Florbetapir and [^{18}F]-T807 PET imaging to investigate amyloid and tau accumulation in subjects with a history of concussions.
- Neuropsychological assessment
- Cohort of subjects with a history of TBIs, mild cognitive impairment and controls.

Case Study

- 39 year old retired NFL athlete
- 22 concussions
- Severe functional complaint

2011

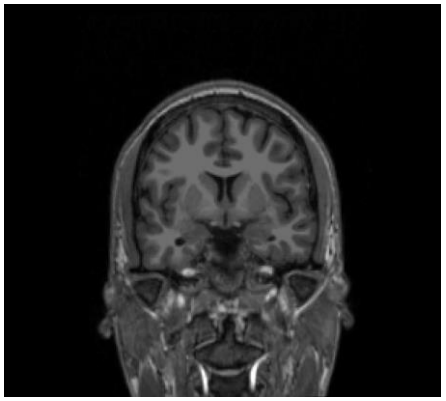

2015

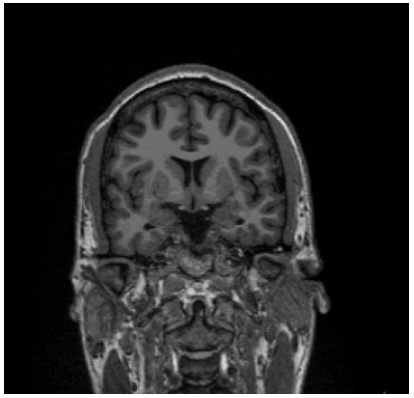

	Previously Collected Data		Current Study
	Nov 2010	June 2011	May 2015
Neuropsychological Testing • Visuo-spatial memory • Verbal reasoning • Verbal fluency • Executive functioning • Fine motor	✓		✓
• Verbal memory • Semantic Fluency • Working memory • Narrative memory • Word Retrieval			✓
Magnetic Resonance Imaging		✓	✓
Tau and Amyloid PET Imaging			✓

22 Concussions In 25 years

Games Played and Recorded Concussions by Year

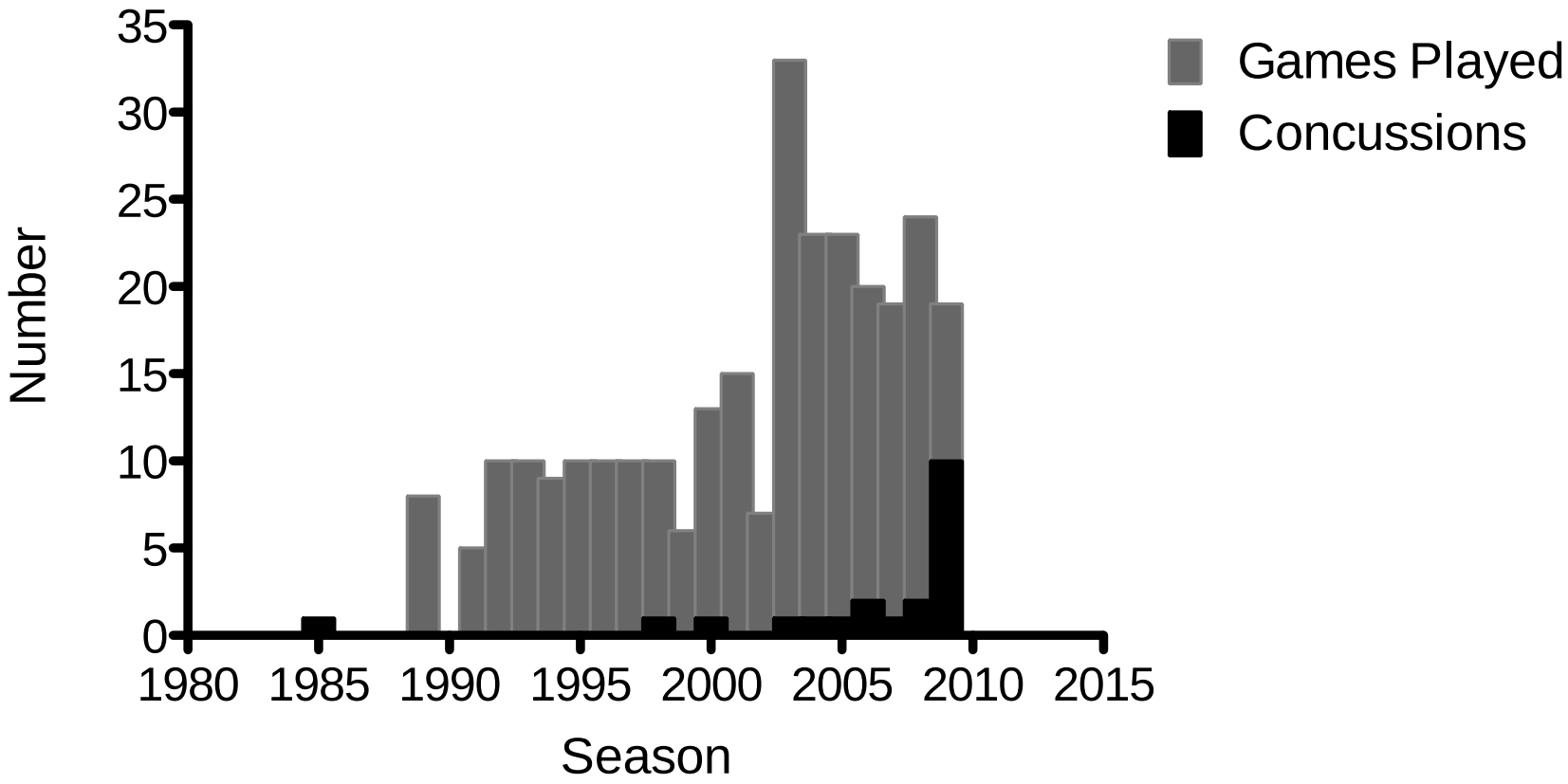

Note: The last concussion from the 2009 season was incurred in 2010. The concussion incurred in 1985 was due to falling from a tree, not from football.

Neuropsychological Decline

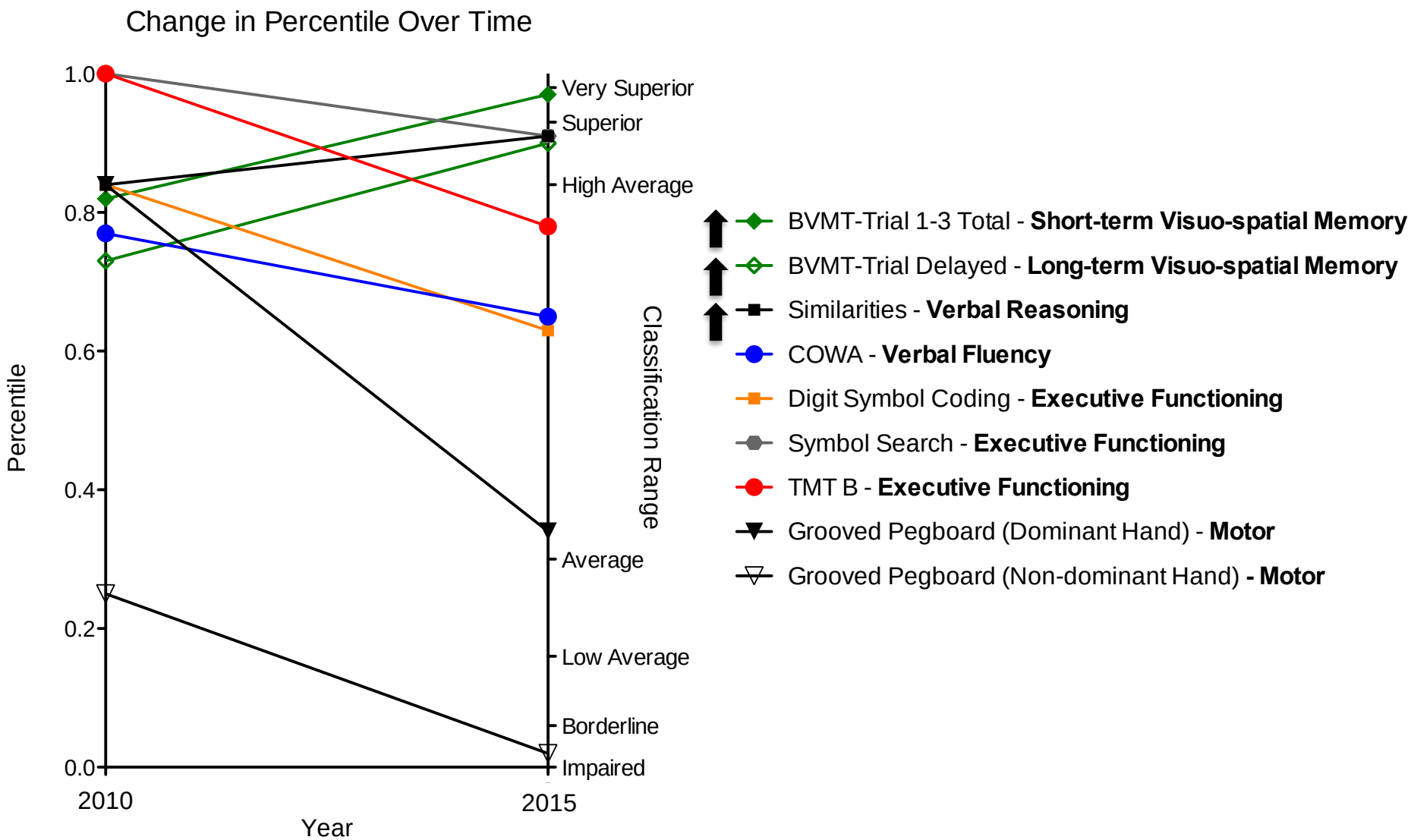

Word retrieval and narrative memory are below average

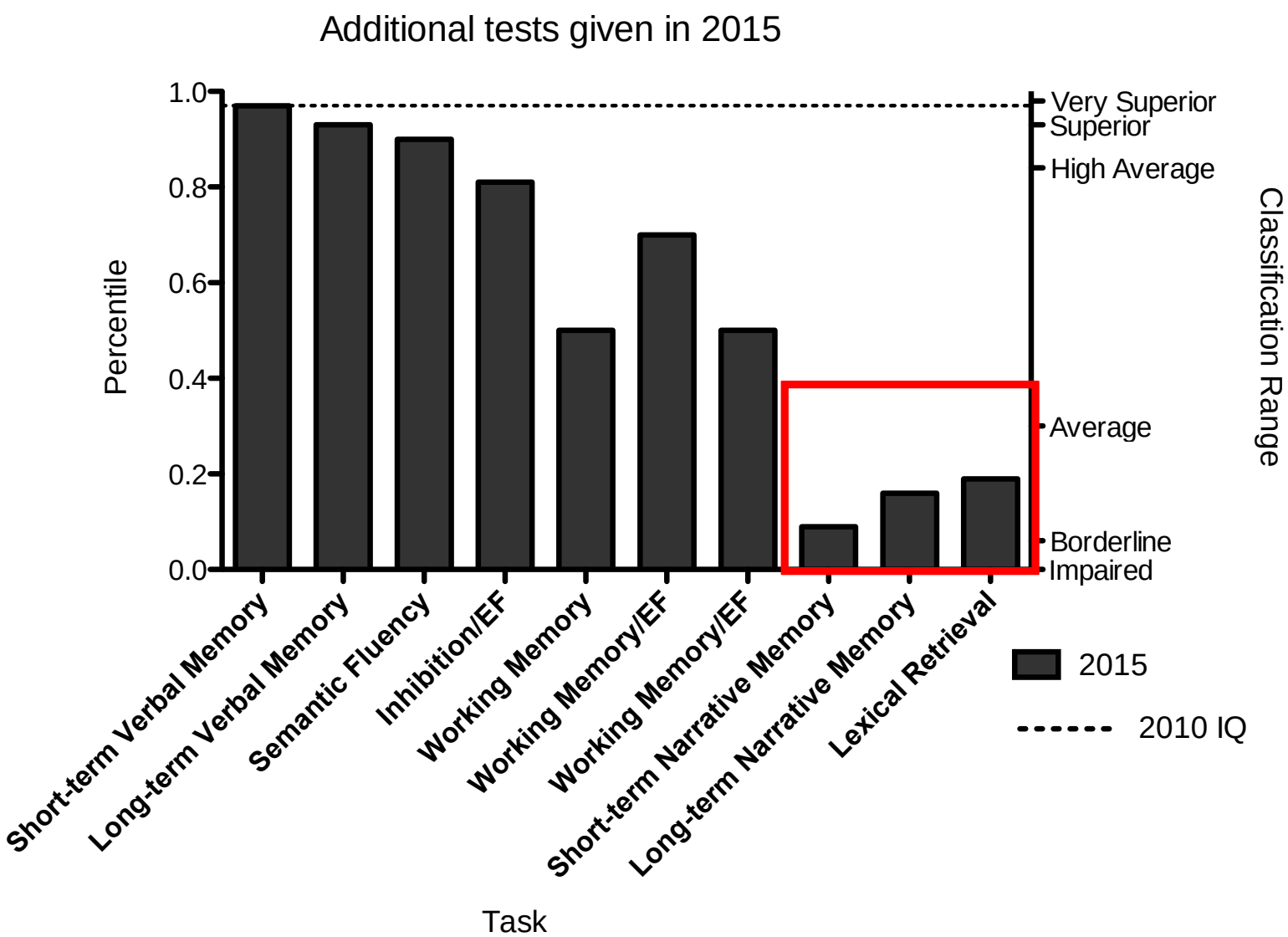

Diffuse cortical thinning over time

Percent change in cortical thickness from 2011 to 2015

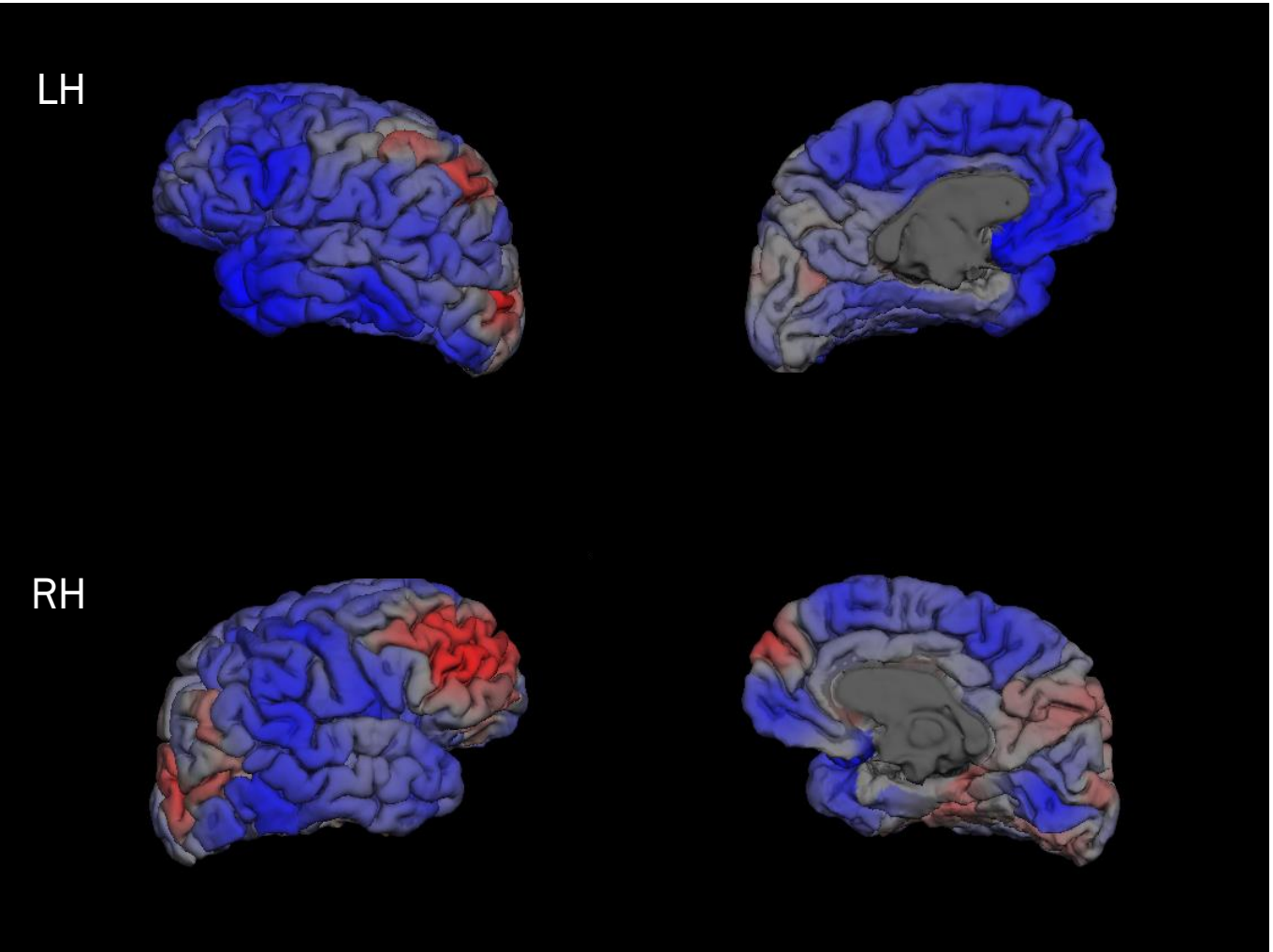

Lateral:

- Broca's area (pars opercularis, pars triangularis)
- Lateral orbitofrontal gyrus
- Temporal pole
- Inferior temporal gyrus

Medial:

- Medial orbitorfrontal gyrus
- Superior frontal gyrus

Positive (Thickening)

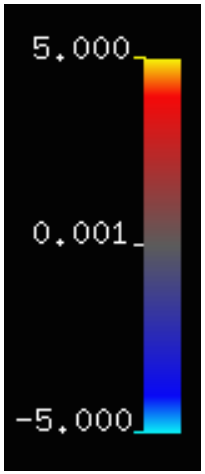

Negative (Thinning)

Cortical thinning is greatest in the left frontal and temporal areas

Percent change in cortical thickness from 2011 to 2015

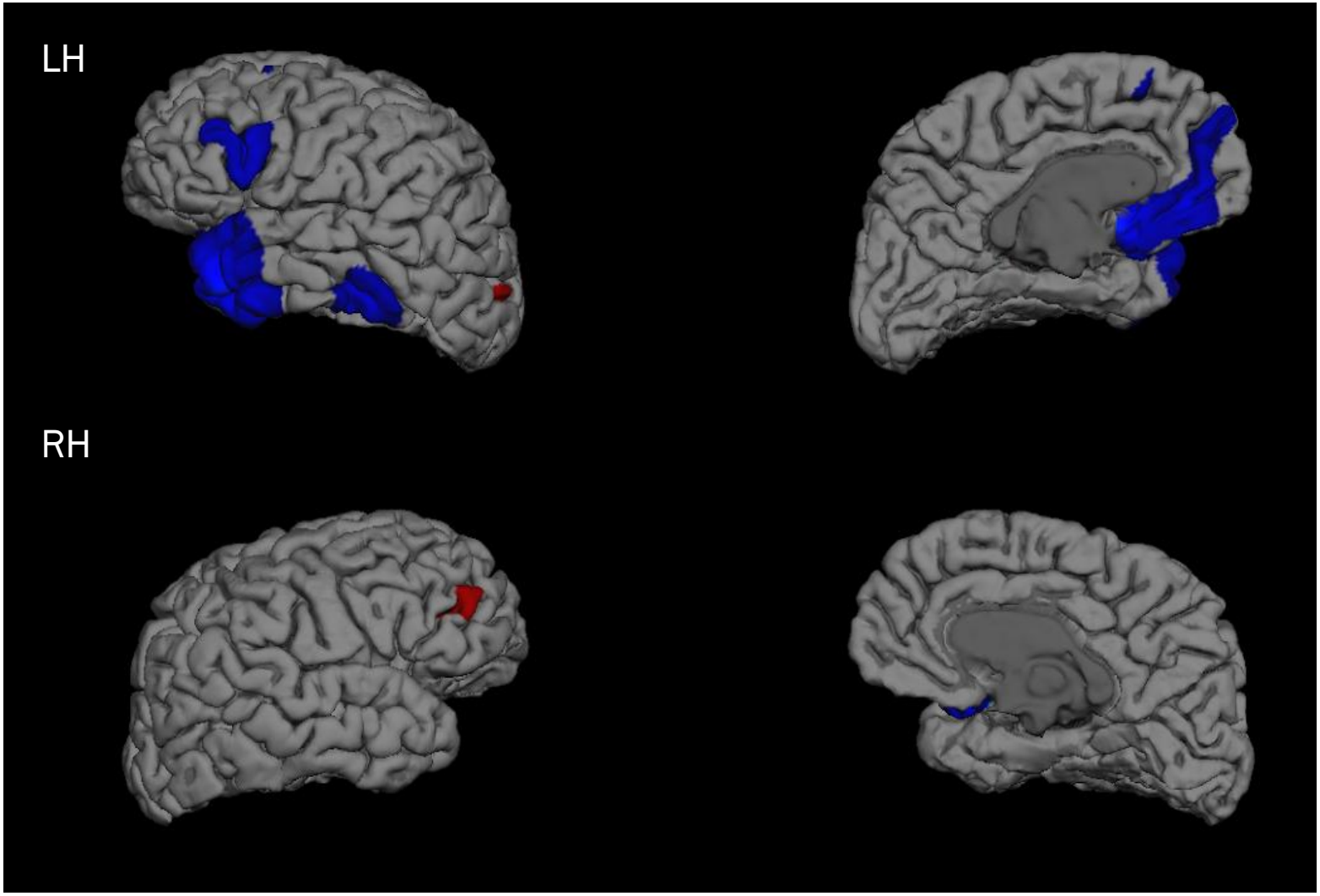

Positive (Thickening)

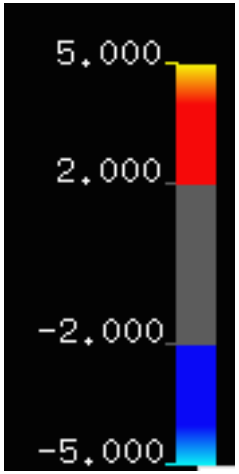

Negative (Thinning)

Subcortical volume decreases are greatest in the basal ganglia

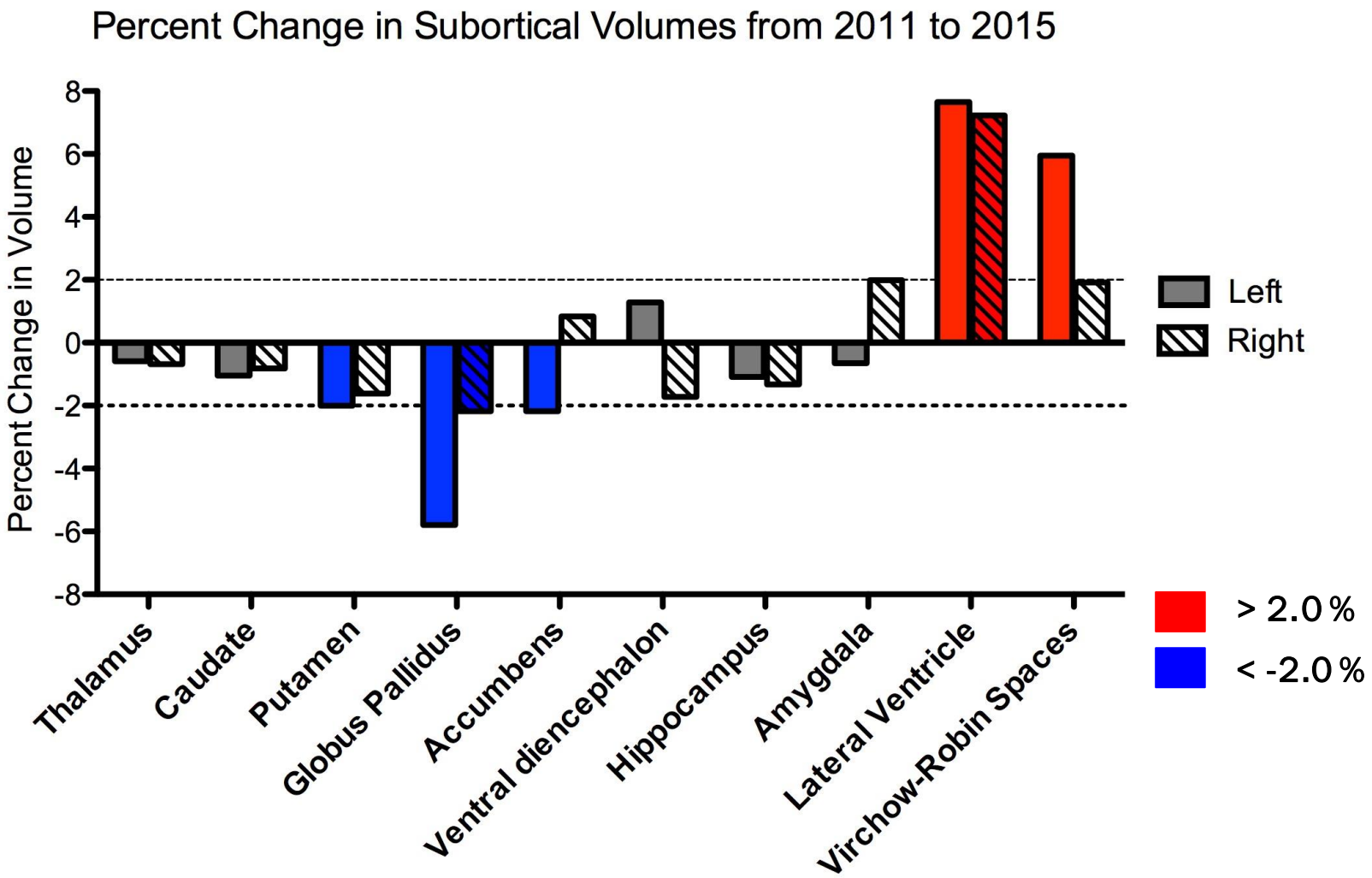

Negative PET [^{18}F]-Florbetapir Scan

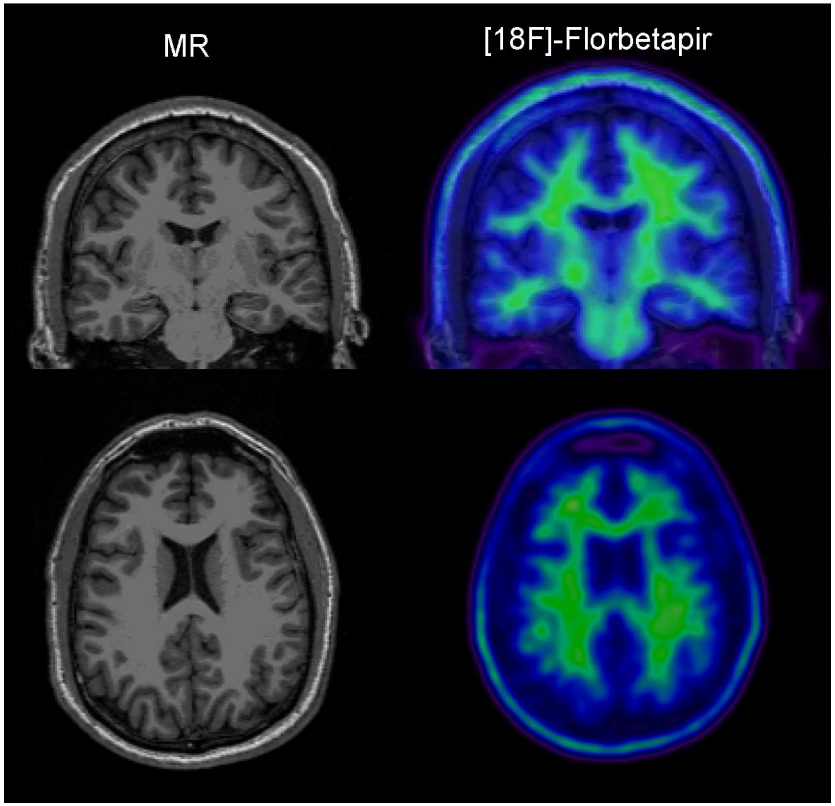

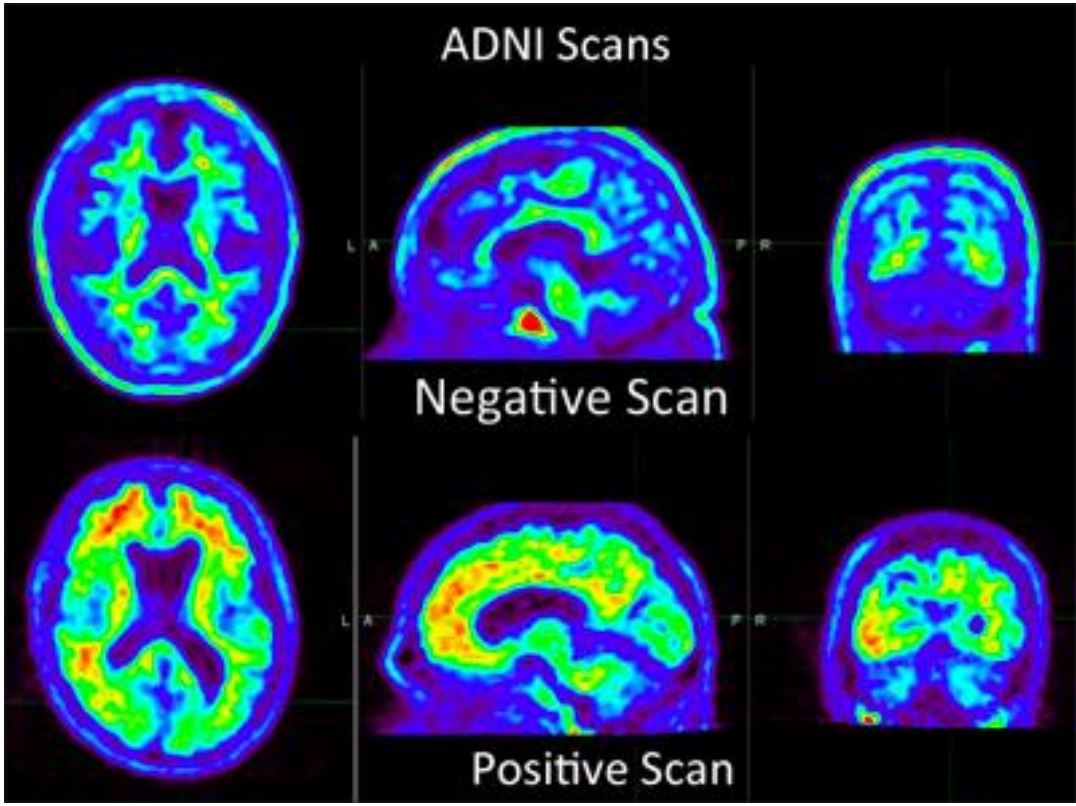

Possible presence of diffuse Tau detected via [^{18}F]-T807 PET

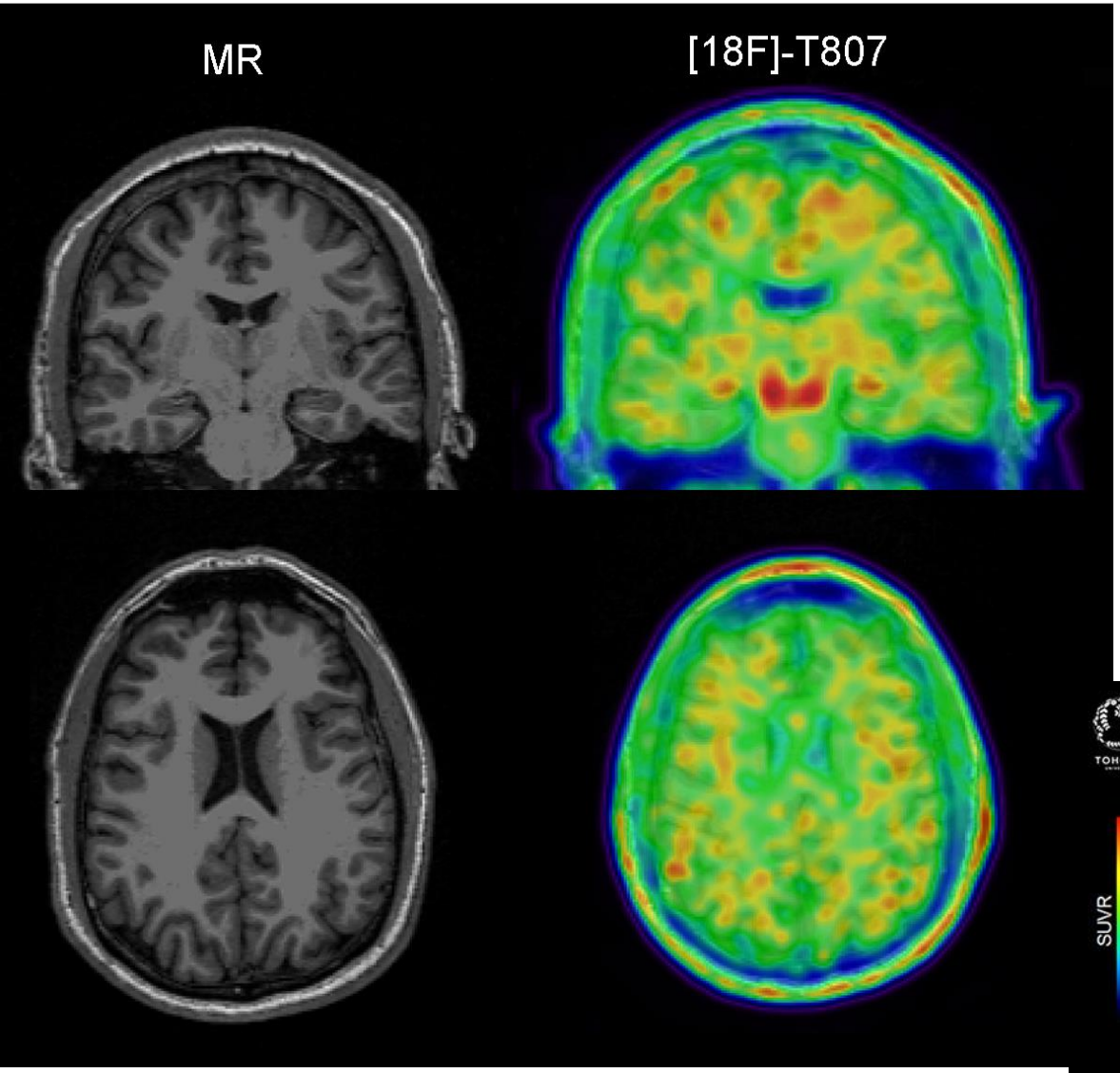

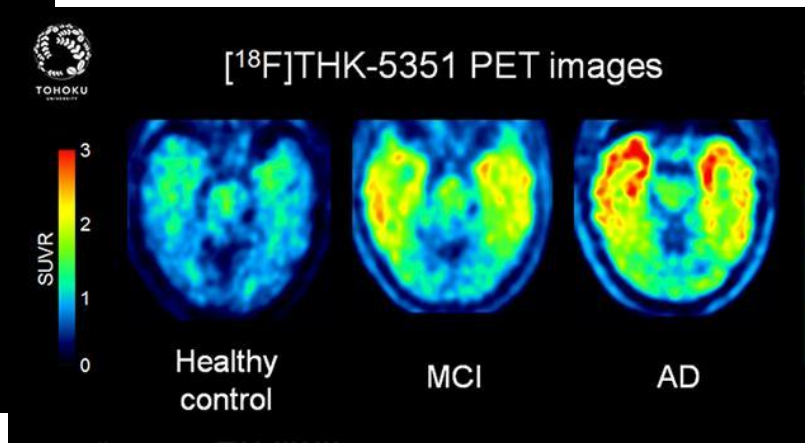

Conclusions

- Cortical thinning in left-lateralized medial frontal, Broca's area and lateral temporal regions
- Subcortical volume decreases greatest in basal ganglia
- Amyloid negative, Tau positive (?)
- Brain changes partially mirror behavioral impairments in this case study
  - But, how does this differ from normal aging?
  - What is causing *severe* symptoms?

Summary: Tauopathy imaging in chronic post TBI subjects

- Early days, cannot yet definitively state which tauopathy imaging signal is authentic
- Both FDDNP and T807/AV1451 yield signal from mesial temporal lobe, brainstem, basal ganglia in CTE and other non-AD tauopathies.
- Some recent T807/AV1451 subjects studied by Sinai and UCSF groups reveal retention in white matter and at grey-white junction, consistent with CTE pattern as defined by 2015 NINDS CTE Consensus

Collaborators and Sponsors

Icahn School of Medicine

- Sam Gandy, M.D.
- Mariel Pullman
- Mary Sano, Ph.D.
- Patrick Hof, M.D.
- Lale Kostakoglu, M.D.
- Karin Knesaurek, M.D.
- Jennifer Short
- Ash Rafique
- Wayne Gordon, M.D.
- Kristen Dams-O'Connor, M.D.
- Corey Fernandez

Boston University

- Robert Cantu, M.D.

MGH, Boston

- Neil Vasdev, M.D., Ph.D.

MNI, New Haven

- Ken Marek, M.D.
- John Seibyl, M.D.

University of Virginia

- James Stone, M.D.

Cornell-Burke

- Barry Jordan, M.D.

University of Florida

- Steve DeKosky, M.D.

Washington University

- David Brody, M.D., Ph.D

NEW REFERRALS WELCOME
TRAVEL, LODGING, HONORARIUM OFFERED

Alzheimer's Drug Discovery Foundation

MSTAR

Avid Radiopharmaceuticals